

Clinical Results of Topography-based Customized Ablations in Highly Aberrated Eyes and Keratoconus/Ectasia With Cross-linking

David T.C. Lin, MD, FRCSC; Simon Holland, MD, FRCSC;
Johnson C.H. Tan, MBBS, FRCSEd(Ophth), FAMS; Gregory Moloney, MBBS, FRCSC, FRANZCO

ABSTRACT

PURPOSE: To report results of a series of highly aberrated corneas treated with a topography-guided excimer laser ablation.

METHODS: Retrospective, nonrandomized, consecutive series of eyes treated with topography-guided photorefractive keratectomy (TG-PRK) with the customized topographical neutralization technique (TNT). Cases included postoperative refractive surgery decentered ablations, optical zone enlargement, asymmetrical astigmatism, postoperative radial keratotomy (RK), postoperative keratoplasty, keratoconus combined with collagen cross-linking (CXL), and postoperative LASIK ectasia combined with CXL. Uncorrected distance visual acuity (UDVA), corrected distance visual acuity (CDVA), and manifest refraction were analyzed preoperatively and 6 months postoperatively.

RESULTS: In decentered ablation cases, 94% of 37 eyes were within 1.00 diopter (D) of the attempted refractive outcome, with 76% within 0.50 D. Mean topographic, central, optical zone of uniform (monodiotropic) power increased from 3.5 to 5.2 mm in 25 eyes. Thirty-one eyes treated for asymmetrical astigmatism showed improvement in cylinder from mean 1.31 to 0.52 D. Ten of 11 eyes treated for previous RK astigmatism achieved postoperative UDVA 20/40 or better. Twenty-seven eyes with postoperative keratoplasty astigmatism were treated, with 7 (25.9%) eyes gaining ≥ 2 lines and 12 (44.4%) eyes gaining ≥ 1 line of CDVA. Of eyes with keratoconus that were treated using TG-PRK with CXL, 42 (58%) eyes had UDVA 20/40 or better, and 66 (92%) eyes had CDVA 20/40 or better. Twelve (71%) of 17 eyes treated for postoperative LASIK ectasia using TG-PRK with CXL had UDVA 20/40 or better. Nine (53%) eyes gained ≥ 2 lines of CDVA.

CONCLUSIONS: Topography-guided laser treatment with custom TNT, combined with CXL in keratoconus and ectasia, is an effective, safe, and increasingly predictable option for highly aberrated corneas. [*J Refract Surg.* 2012;28(11 Suppl):S841-S848.]
doi:10.3928/1081597X-20121005-06

Topography-guided excimer laser ablation was introduced more than 10 years ago and was used to treat highly aberrated corneas. Currently, no topography-guided systems are approved for use in the United States.

The concept of topography-guided laser ablation is to modify the cornea by treating anatomical rather than physiological changes, and consequently, is less influenced by intraocular factors than wavefront-guided laser ablation. One of the challenges of topography-guided treatment is that any shape change will have a refractive effect. Thus, if only a topography-guided correction is performed, with subsequent improved topography and corrected distance visual acuity (CDVA), the refraction is unpredictable. WaveLight Allegretto Wave (Alcon Laboratories Inc, Ft Worth, Texas) treatments usually result in a net hyperopic ablation profile effect, leading to increased myopia requiring a second refractive treatment. The custom topographical neutralization technique (TNT) was developed¹ to provide a neutralizing refractive effect to compensate for such changes in a single treatment. Prior to the introduction of the topography-guided laser, wavefront-guided treatment was used for aberrated corneas, but this proved to be difficult in capturing satisfactory and repeatable images, thereby not allowing for a satisfactory treatment in severely aberrated eyes. Topography-guided laser ablation may be valuable in this situation by treating shape rather than physiological changes.

We have used the topography-guided laser ablation profile in a wide range of aberrated eyes, including decentered ablations, optical zone enlargement, asymmetrical astigmatism, postoperative radial keratotomy (RK), postoperative kerato-

From Pacific Laser Eye Centre (Lin, Holland) and the Eye Care Centre, Cornea Unit, Department of Ophthalmology, University of British Columbia (Holland, Tan, Moloney), Vancouver, Canada; and National Healthcare Group Eye Institute, Tan Tock Seng Hospital, Singapore (Tan).

Dr Holland receives research support from Alcon Laboratories Inc and travel support from Allergan and Bausch & Lomb. The remaining authors have no financial interest in the materials presented herein.

Correspondence: Simon Holland, MD, FRCSC, Pacific Laser Eye Centre, 1401 W Broadway, Fifth Fl, Vancouver BC, Canada V6H 1H6. Tel: 604.736.2625; Fax: 604.736.2699; E-mail: simon_holland@telus.net

plasty, keratoconus combined with collagen cross-linking (CXL), and postoperative LASIK ectasia with combined CXL.

We present a review of our clinical results since 2007 using the Allegretto Wave excimer laser. Our results from 2003 to 2007 have been reported previously.¹

PATIENTS AND METHODS

This was a retrospective, nonrandomized, consecutive, case series of patients undergoing topography-guided laser ablation performed by chart review since 2007. The study was approved by an internal review board (Pacific Laser Eye Centre). Informed consent was obtained from all patients in accordance with the Declaration of Helsinki. All surgeries were performed at the Pacific Laser Eye Centre, Vancouver BC, Canada. Patients treated were predominantly from British Columbia, but included those from the United States, the rest of Canada, and internationally.

All patients were treated with topography-guided ablation using the WaveLight Allegretto, which uses the Allegretto Wave Topolyzer with the T-CAT software (Alcon Laboratories Inc). Custom TNT was used to treat the induced and manifest refractive error.

Custom TNT is probably best shown with a clinical example, such as keratoconus (Fig 1). Topographical neutralization technique consists of four steps: 1) neutralization of plano topographic treatment, which in this case results in a hyperopic shift; 2) neutralization of the topographic cylinder, which is achieved by inputting positive cylinder (0.00 +1.25 × 120); 3) neutralization of the cylinder and spherical shift combined (-0.50 +1.25 × 120); and 4) neutralization of the manifest refraction to target a plano outcome (-8.75 -2.25 × 30, which is shown as -7.92 -1.80 × 30 on the corneal plane, where the treatment is applied, either under the flap in LASIK or after transepithelial phototherapeutic keratectomy [PTK] in photorefractive keratectomy [PRK]).

Patients underwent custom TNT for decentered optical zones after previous refractive surgery; small optical zones; irregular or asymmetrical astigmatism; postoperative radial keratotomy; postoperative keratoplasty astigmatism; keratoconus with CXL; and postoperative LASIK ectasia with CXL. Data collected in all groups included pre- and postoperative uncorrected distance visual acuity (UDVA), corrected distance visual acuity (CDVA), manifest refraction, symptom score, topography, and keratometry.

Symptoms were evaluated by patient history before and 6 to 12 months after surgery, as obtained by chart review. Symptoms were reported as blurred or hazy vision, halos and starbursts, poor night vision, image

doubling, and glare. A separate evaluation was done using a 10-point questionnaire of glare and halos in the keratoconus and ectasia group before and 6 months after surgery.

Custom TNT was used in all cases by two surgeons (D.T.C.L., S.H.). Planning was performed involving the four steps described above.

All cases of LASIK retreatment for decentered ablation and small optic zone involved lifting the flap. Using topical anesthesia (proparacaine 0.5%, Alcaine; Alcon Laboratories Inc), the flap edge was marked at the slit lamp with a 30-gauge needle. The patient was positioned under the laser microscope and the flap edge lifted with a Sinsky hook (Storz, Rochester, New York). A Suarez spatula (Storz) was used to lift the entire flap at the edges to the hinge. A cyclodialysis spatula was introduced at the hinge, and the flap adhesions broken away from the hinge. The flap was fully lifted and the topography-guided ablation was performed. After the ablation, 70% ethanol in balanced saline solution (BSS) was placed on the stromal bed epithelial edges for 30 seconds and any previous stromal epithelial anomalies or ingrowth removed with a spatula. The flap was repositioned with BSS and dried in position. A bandage contact lens (SofLens 66; Bausch & Lomb, Rochester, New York) was placed overnight in all cases.

Patients undergoing PRK received transepithelial PTK and topography-guided (TG)-PRK with the Allegretto Eye-Q 400-Hz excimer laser (Alcon Laboratories Inc). The TNT was used as illustrated (see Fig 1). Mitomycin C (MMC) 0.02% was instilled for 15 to 30 seconds, irrigated away with BSS, after which a bandage contact lens was fit, remaining in place until full reepithelialization. Fluoromethalone 0.12% eye drops were given for 3 months, with a tapered dosing schedule, modified based on refraction. Patients were followed indefinitely with their comanaging doctors with results requested at 1, 3, 6, and 12 months postoperatively and annually thereafter.

For treatment planning with TG-PRK using T-CAT software for keratoconus and postoperative LASIK ectasia with CXL (since 2009), TNT was modified with the refractive treatment being targeted at -1.25 D sphere, anticipating possible reduction of postoperative keratometry, due to cross-linking. The refractive treatment was limited by a minimal residual stromal depth of 300 µm and maximum stromal ablation of 80-µm depth. Corneal epithelium was removed by transepithelial laser followed by TG-PRK with T-CAT software, and the modified custom TNT. Riboflavin 0.1% in dextran was applied every minute until visualization of riboflavin aqueous staining. In corneas

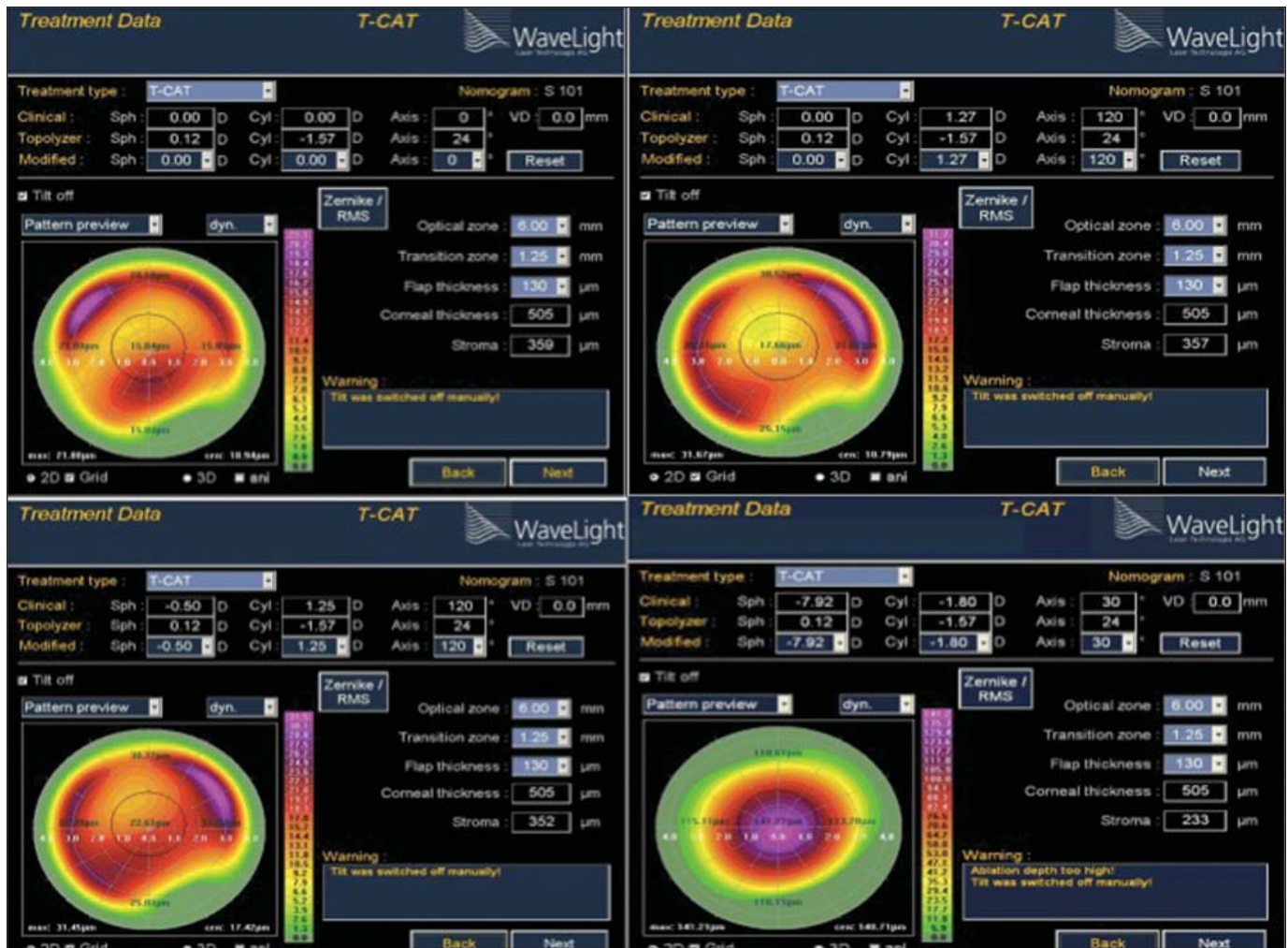


Figure 1. Custom topographic neutralization technique for keratoconus.

with stromal depth <400 μm , riboflavin in hypotonic solution was used in a 1:3 ratio to achieve swelling to 400 μm . Ultraviolet irradiation at 370 nm wavelength, using the Peschke unit (PESCHKE Meditrade GmbH, Nuenenberg, Switzerland), was applied at 3 mW/cm^2 (total up to 5.4 J/m^2). The eye was irrigated with BSS, and MMC 0.02% was applied for 15 to 30 seconds, after which the stroma was reirrigated with BSS. A bandage contact lens was applied.

RESULTS

DECENTERED ABLATIONS

Fifty-four eyes with decentered ablation zones after previous LASIK underwent topography-guided LASIK, with 37 having sufficient follow-up information for analysis. At 6 months postoperatively, average centration improved from 1.1 mm preoperatively to 0.4 mm postoperatively. Improved UDVA was achieved

in 64% of eyes, with 92% of eyes having 20/40 or better and 74% having 20/20 or better. Furthermore, 5% of eyes gained 2 lines of CDVA, with 25% gaining 1 line and no eyes losing ≥ 2 lines. The refractive outcomes showed 94% of eyes within 1.00 diopter (D) and 76% within 0.50 D of targeted refraction. Thirty-three of 37 patients were satisfied with their results. As an early postoperative example, Figure 2 demonstrates the 1-week postoperative results for a decentered ablation treatment that showed marked improvement of vision and symptoms. Figure 3 shows the long-term results of a 51-year-old man with an incomplete LASIK flap and central island whose topographic outcome markedly improved 18 months after TG-PRK.

OPTICAL ZONE ENLARGEMENT

Forty-nine eyes after previous LASIK underwent custom TNT LASIK retreatment with 25 eyes available for analysis at 6 months postoperatively. Mean postopera-

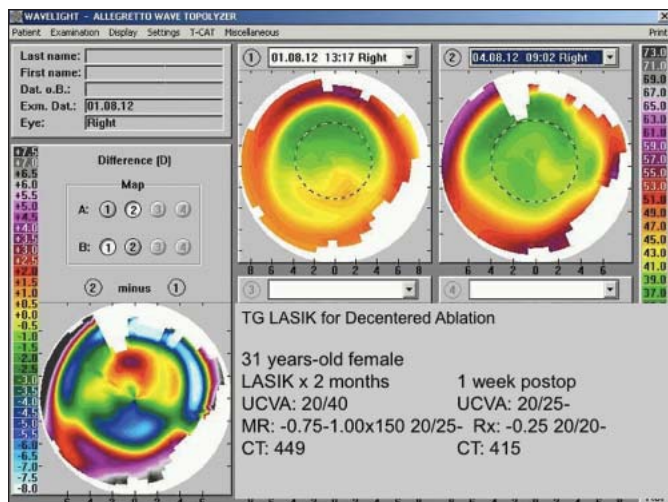


Figure 2. Early results of topography-guided LASIK retreatment for short flap and decentered ablation.

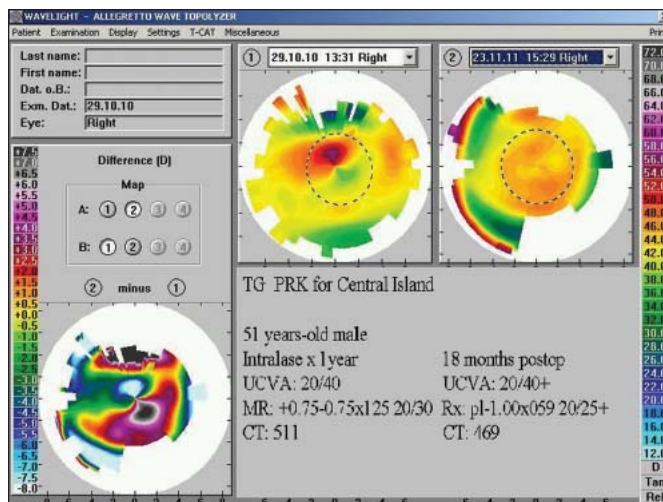


Figure 3. Decentered ablation treated with topography-guided photorefractive keratectomy for incomplete femtosecond laser flap.

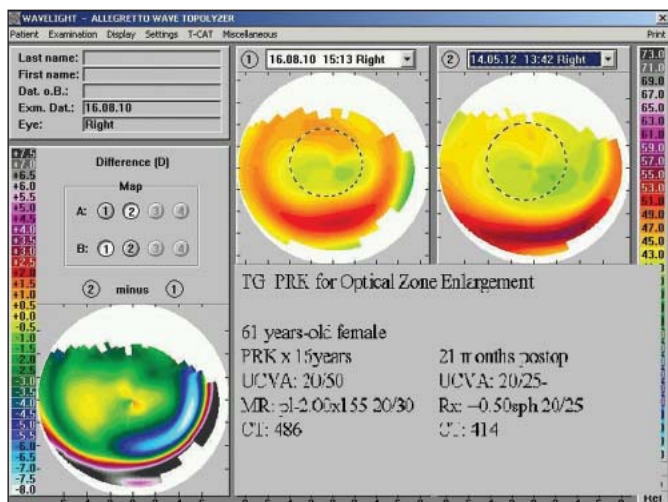


Figure 4. Enlargement of optical zone with topography-guided photorefractive keratectomy.

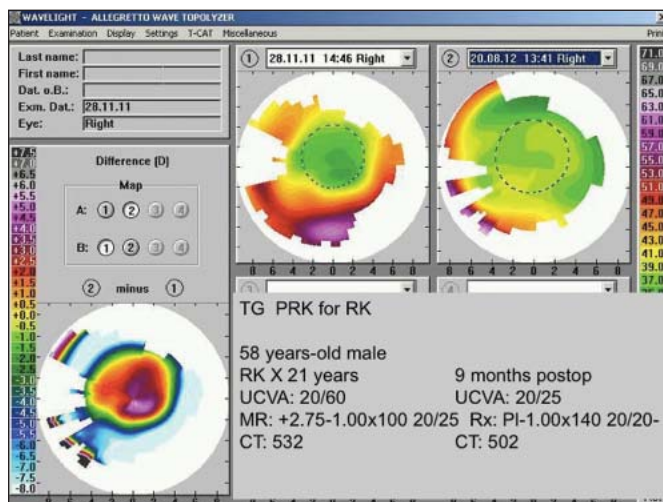


Figure 5. Topography-guided photorefractive keratectomy for postoperative radial keratotomy.

tive topographic central optical zone of uniform (monodiotropic) power was 5.2 mm, compared to 3.5 mm preoperatively (Fig 4). Postoperatively, 88% achieved CDVA 20/40 or better, 86% 20/25 or better, and 62% 20/20 or better, with 4% showing CDVA improvement of 2 lines. Only 6% of eyes lost 1 line of CDVA, and none lost ≥ 2 lines. The refractive outcome was found to be predictable, with 92% of eyes within 1.00 D and 81% within 0.50 D of attempted refraction. Overall, 40 (82%) of 49 eyes reported symptomatic improvement.

ASYMMETRICAL ASTIGMATISM

Fifty-six eyes underwent TG-PRK for asymmetrical astigmatism. Thirty-nine eyes were available for analysis. Preoperatively, only 79% of eyes had CDVA 20/20, whereas 10% had 20/25 and another 10% had 20/30.

Postoperatively, 86% of eyes achieved CDVA 20/20 or better with 20% gaining ≥ 1 line, and no eyes losing CDVA from baseline. Beyond the modest improvement in CDVA, the change in cylinder was more relevant, from a mean of 1.31 D (range: 0.00 to 5.75D) preoperatively to 0.52 D (range: 0.00 to 1.50 D) postoperatively.

RADIAL KERATOTOMY

Topography-guided PRK was performed on 11 eyes with irregularity due to previous RK. Preoperatively, 8 (72.7%) eyes had UDVA 20/80 or worse. After TG-PRK, 91% had UDVA 20/40 or better. Mean preoperative cylinder was 2.00 D (range: 0.00 to 4.50 D), improving to 0.89 D (range: 0.00 to 1.50 D) after the procedure. Figure 5 shows an improvement in the topographic zone size and regularity, leading to an

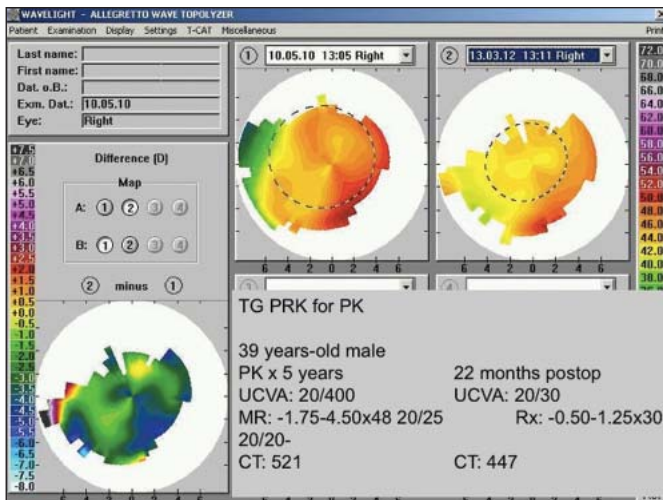


Figure 6. Improvement in uncorrected distance visual acuity and astigmatism after topography-guided photorefractive keratectomy for postoperative keratoplasty astigmatism.

improved refractive outcome and UDVA and CDVA after treatment.

POSTOPERATIVE KERATOPLASTY

Forty eyes underwent TG-PRK for postoperative keratoplasty astigmatism. Analysis was available for 27 eyes with follow-up of at least 6 months. At 6 months, 46% of eyes achieved UDVA 20/40 or better, with none having this vision prior to treatment. Forty-four percent of eyes gained ≥ 1 line of CDVA, whereas 25.9% gained ≥ 2 lines. However, 3 eyes lost 1 line and another 3 lost 2 lines of CDVA at the end of the follow-up period. Mean cylinder improved from 4.46 D (range: 1.75 to 7.50 D) preoperatively to 1.64 D postoperatively (range: 0.00 to 5.50 D). Figure 6 shows the pre- and postoperative topography of a 39-year-old

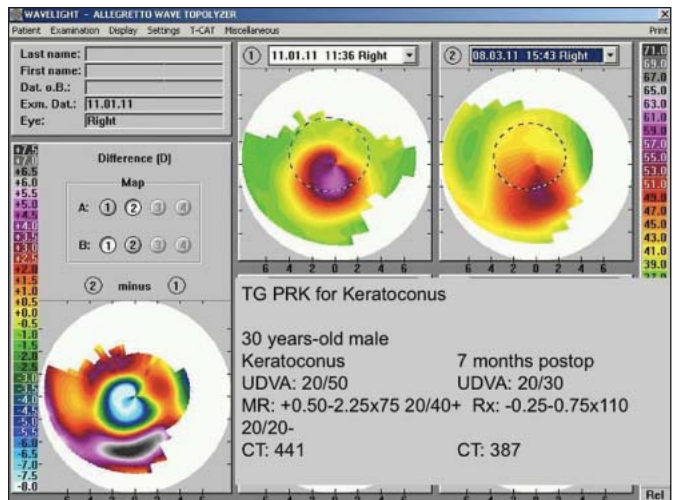


Figure 7. Topography-guided photorefractive keratectomy with cross-linking for keratoconus.

patient with a reduction in topographic and refractive astigmatism of >3.00 D after TG-PRK.

KERATOCONUS WITH CROSS-LINKING

Two hundred seventeen eyes underwent custom TNT TG-PRK for keratoconus combined with CXL during the study period beginning in 2009. All were dissatisfied with or intolerant of specialty contact lenses and were advised that they may need corneal transplant if surgery was not successful (several were already on transplant lists). Seventy-two eyes completed 12-month follow-up with sufficient data for analysis. Postoperatively, 42 (58%) had UDVA 20/40 or better, with 66 (92%) having CDVA 20/40 or better. Forty-three (60%) eyes had 1 line improvement in CDVA, with 17 (24%) showing no change. Nine (12.5%) eyes

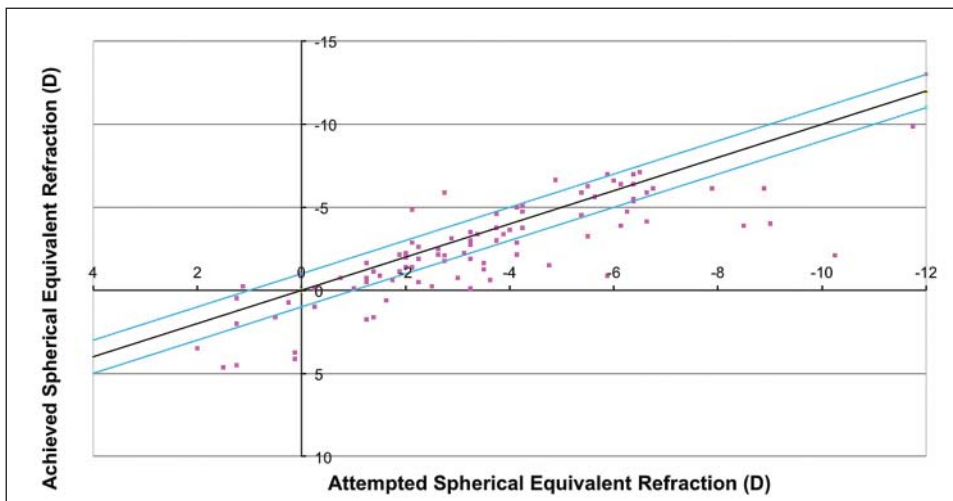


Figure 8. Attempted vs achieved spherical equivalent refraction of keratoconus cases 12 months postoperatively.

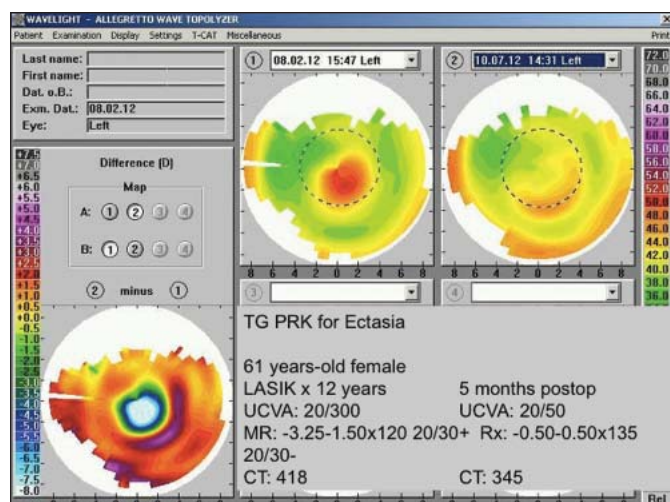


Figure 9. Topography-guided photorefractive keratectomy for postoperative LASIK ectasia.

lost 1 line, and 3 (4%) lost ≥ 2 lines of CDVA (Figs 7 and 8). Mean astigmatism decreased from 2.87 D preoperatively to 1.40 D postoperatively.

Four eyes had a delay in epithelial healing with subsequent haze. In two of these eyes, the haze was sufficient to cause a reduction in CDVA of >2 lines from preoperative CDVA. One eye had herpetic keratitis that required a subsequent PTK, with eventual recovery of preoperative CDVA. Two patients who came from remote areas had difficulties with compliance and follow-up, with one developing severe haze and the other showing keratometric progression. Both subsequently underwent corneal penetrating keratoplasty. Two patients with pellucid marginal degeneration required retreatment.

Improvement in symptoms of glare, halos, and difficulties with night driving were reported in 80% (25 eyes), whereas 8% became worse, and the remaining 12% reported no change.

POSTOPERATIVE LASIK ECTASIA

Twenty-three eyes were treated for postoperative LASIK ectasia with 17 completing at least 6-month follow-up for inclusion in analysis. Twelve (71%) had UDVA 20/40 or better postoperatively in comparison to 12% preoperatively. Nine (53%) eyes gained ≥ 2 lines of CDVA with only 1 eye losing 2 lines. A mean reduction was noted in astigmatism of 2.56 D (Fig 9) and all but 2 eyes symptomatically improved.

The only complication observed was a delay in epithelialization beyond 1 week in two eyes without long-term adverse effect. No progression of ectasia was noted in up to 2-year follow-up.

DISCUSSION

Topography-guided ablation using the WaveLight Allegretto Wave excimer laser has become increasingly popular outside the United States. We first reported our clinical outcomes for highly aberrated corneas in 2008.¹ Our latest results reflect the widening indications for this ablation profile, as the increasing use of CXL allows for its use in keratoconus and ectasia.

Topography-guided laser treatment offers potential advantages in allowing image capture in eyes where reproducible centroids cannot be obtained with wavefront-guided laser technology.^{1,2} These difficult to capture eyes have more severely aberrated corneas, often due to complications of refractive surgery, such as ectasia, decentration, and RK. Hence, they represent a special group of untreated or inadequately treated eyes that contribute to the negative perception of refractive surgery. Beyond this, even in normal eyes, this technology is beginning to gain acceptance, as equivalent outcomes have been reported with topography-guided versus wavefront-guided treatments.³

One challenge of topography-guided treatment is the refractive predictability, as any shape change will have a refractive effect. The custom TNT method has become increasingly valuable in treatment planning to manage and enhance the refractive outcome of the topography-guided treatment. The increasing number of patients in our database also allows us to build off our experience and closely match the treatment plan to similar eyes that have been previously treated, as reference cases. Although our study could be improved with more complete and thorough follow-up, we are limited by our dependence on obtaining results from our referring colleagues, who occasionally encounter these postoperative refractive surgical irregularities.

In reviewing our outcomes, the visual and refractive results of the topography-guided treatment for decentered ablation are similar to our previous results,¹ with improved symptoms of glare, halos, starburst, and difficulty with night driving in all but 4 of the 37 eyes. This was associated with better zone centration on topography and satisfactory UDVA of 20/40 or better in 88% of eyes.

Similar outcomes were achieved in eyes undergoing treatment for small optical zones with larger monodiotropic zones increasing from 3.5 to 5.2 mm. Uncorrected distance visual acuity was 20/40 or better in 88% of these eyes, and approximately 60% achieved an outcome of 20/20, with 82% reporting symptomatic improvement. The first step of neutralizing topographic higher order aberrations in this zone enlargement creates a hyperopic treatment effect and usually requires greater myopic spherical compensation with TNT than the decentered ablation treatment.

Patients with asymmetrical astigmatism had similar CDVA before and after topography-guided treatment, but were noted to have a reduction in measured astigmatism. We found the change in symptoms difficult to assess with lack of a definitive and reproducible quality of vision assessment index for this cohort, as many were referred from outside our local area.

Satisfactory results were also seen when topography-guided ablation was used for RK with a gain in UDVA and reduced astigmatism. Before treatment, 8 (78%) eyes had UDVA of 20/80 or worse, and postoperatively, 10 (91%) eyes achieved UDVA 20/40 or better.

Our impression with the postoperative keratoplasty cohort is that irregular astigmatism is more challenging to treat, due to greater regression and haze development, even with the use of topical MMC. Despite this challenge, half of the patients achieved UDVA 20/40 or better in comparison to none of the eyes before treatment.

Excellent results for topography-guided treatment of keratoconus combined with CXL have been reported for several years from countries having access and regulatory approval to perform both procedures.⁴⁻¹⁰ Previously, sequential treatment was performed with initial CXL followed by TG-PRK, after first achieving keratometric and topographic stability. We prefer the simultaneous technique with initial TG-PRK followed immediately by CXL. Kanellopoulos and Binder^{6,7} have published a large comparative series of 325 eyes with mean 3-year follow-up, and showed that better outcomes were achieved with the simultaneous technique in comparison to sequential treatment. One reservation and limitation when using this technique is that the unpredictable flattening effect of CXL may lead to an unexpected, hyperopic overcorrection. In our study, 8 of 75 eyes had a hyperopic spherical equivalent of +1.00 to +2.00 D after 1 year, when targeting an outcome of -1.25 D. This hyperopic surprise, however, was not the norm; rather there was a trend towards myopia (see Fig 8), due to the hyperopic ablation profile of most keratoconus treatments when using the WaveLight TG-PRK (T-CAT) program.

Our results in keratoconus were similar to the published experiences of others,⁷⁻⁹ with 42 (58%) eyes achieving UDVA 20/40 or better and 66 (92%) having CDVA 20/40 or better, with a satisfactory safety profile. Stojanovic et al⁸ reported 12-month results of 12 eyes that had undergone topography-guided ablation with CXL in a single combined procedure, achieving a mean improvement in UDVA from 20/1000 to 20/125, and mean improvement in CDVA from 20/57 to 20/35. Although Stojanovic et al treated eyes with both keratoconus and pellucid marginal degeneration,⁸ it is our

impression that eyes with pellucid marginal degeneration appear to have more regression. The 2 eyes in our study that were retreated both had pellucid marginal degeneration, and we believe the regression they experienced is because CXL is less effective in the peripheral cornea, where the ectasia is greatest. Overall, we also noted a diffuse, faint, anterior stromal haziness after CXL that was not visually significant.

In eyes with postoperative LASIK ectasia, good results have also been reported with simultaneous TG-PRK and CXL.¹⁰ In 2001, Kanellopoulos¹⁰ reported tomographic stability and improved CDVA of 20/40 or better in 27 of 32 eyes with follow-up of more than 1.5 years. In our study, we report 17 eyes with postoperative LASIK ectasia who underwent TG-PRK with simultaneous CXL with at least 6-month follow-up. With a similar good outcome, 12 (71%) of 17 eyes achieved UDVA 20/40 or better with more than half (53%) gaining ≥ 2 lines of CDVA. Overall mean topographic astigmatism was reduced by 2.56 D.

Topography-guided laser treatment, combined with CXL in keratoconus and ectasia, is proving to be an effective and safe option for highly symptomatic patients with aberrated corneas from a wide range of conditions. Increasingly predictable treatment is possible with custom TNT.

AUTHOR CONTRIBUTIONS

Study concept and design (D.T.C.L., S.H.); data collection (S.H.); analysis and interpretation of data (S.H., J.C.H.T., G.M.); drafting of the manuscript (S.H., J.C.H.T.); critical revision of the manuscript (D.T.C.L., S.H., J.C.H.T., G.M.); statistical expertise (J.C.H.T.); supervision (S.H.)

REFERENCES

1. Lin DT, Holland S, Rocha KM, Krueger RR. Method for optimizing topography-guided ablation of highly aberrated eyes with the ALLEGRETTO WAVE excimer laser. *J Refract Surg.* 2008;24(4):S439-S445.
2. Krueger RR. Corneal topography vs ocular wavefront sensing in the retreatment of highly aberrated post-surgical eyes. *J Refract Surg.* 2006;22(4):328-330.
3. Falavarjani KG, Hashemi M, Modarres M, Sanjan MS, Darvish N, Gordiz ZA. Topography-guided vs. wavefront-optimized surface ablation for myopia using the wavelight platform: a contralateral eye study. *J Refract Surg.* 2011;27(1):13-17.
4. Kanellopoulos AJ. Topography-guided custom retreatments in 27 symptomatic eyes. *J Refract Surg.* 2005;21(5):S513-S518.
5. Pasquali T, Krueger R. Topography-guided laser refractive surgery. *Curr Opin Ophthalmol.* 2012;23(4):264-268.
6. Kanellopoulos AJ, Binder PS. Collagen cross-linking (CCL) with sequential topography-guided PRK: a temporizing alternative for keratoconus to penetrating keratoplasty. *Cornea.* 2007;26(7):891-895.
7. Kanellopoulos AJ. Comparison of sequential vs same-day simultaneous collagen cross-linking and topography-guided PRK for treatment of keratoconus. *J Refract Surg.* 2009;25(9):S812-S818.

8. Stojanovic A, Zhang J, Chen X, Nitter TA, Chen S, Wang Q. Topography-guided transepithelial surface ablation followed by corneal collagen cross-linking performed in a single combined procedure for the treatment of keratoconus and pellucid marginal degeneration. *J Refract Surg.* 2010;26(2):145-152.
9. Kymionis GD, Portaliou DM, Kounis GA, Limnopoulou AN, Konstadakis GA, Grentzelos MA. Simultaneous topography guided photorefractive keratectomy followed by corneal collagen cross-linking for keratoconus. *Am J Ophthalmol.* 2011;152(5):748-755.
10. Kanellopoulos AJ, Binder PS. Management of corneal ectasia after LASIK with combined, same-day, topography-guided partial transepithelial PRK and collagen cross-linking: the Athens Protocol. *J Refract Surg.* 2011;27(5):323-331.